

Letters to the Editor

Extrahepatic manifestations of Hepatitis C virus infection: the slowly unraveling picture of oral lichen planus

To the Editor:

Hepatitis C virus (HCV) infection is associated with various extrahepatic manifestations. Nevertheless, although several epidemiological arguments suggest that HCV could be implicated in their pathogenesis, existing studies have not been able to determine whether, and by which mechanisms, it plays a direct causal role. With regard to oral lichen planus (OLP), many studies performed mainly in Italy, Japan, Spain have described a strong epidemiological association with HCV infection. On the contrary other reports from different geographic areas, as well as some from the same countries, have found no significant correlation between these conditions. Thus, controversies still exist as to whether HCV infection can have a role in OLP pathogenesis. However, new epidemiological data on the real prevalence of HCV infection in Southern Italy are now available [1–4]. In this context, we have compared the epidemiological features of HCV infection in 600 OLP patients (390 women and 210 men; mean age 52.6 years, range 18–83 years) with the prevalence of HCV infection in general population in order to extrapolate new results towards the association with OLP. All cases had characteristic oral lichenoid lesions and underwent oral biopsy that confirmed the diagnosis. No patient, on the basis of histopathological features and clinical data, was suspected of having drug- or restoration-related lichenoid reactions. Subject were screened for the presence of anti-HCV by a second generation enzyme-linked immunosorbent assay (ELISA II; Orto Diagnostic and Chiron Corp., Emerville CA, USA) according to manufacturer's instructions. Anti-HCV immunoreactivity by enzyme immunoassay was confirmed by a supplemental second-generation recombinant immunoblot assay (RIBA 2; Orto Diagnostic and Chiron Corp., Emerville CA, USA). Differences in proportion between OLP patients and the control group were evaluated using the chi-squared test. A *P*-value of <0.05 was considered significant. Of the total of 600 OLP patients studied, 169 tested anti-HCV reactive with ELISA II; among these, 165 tested positive with RIBA and four had indeterminate results. Thus, the overall anti-HCV ELISA II-positive RIBA-confirmed prevalence was 27.5% (165 of 600 subjects). Categorizing OLP patients in five age groups, the prevalence was 0.0% (0/3) in subjects younger than 30 years, 4.6% (3/65) in 30–39 years age group, 12.5% (15/120) in 40–49 years age group, 27.5% (55/200) in 50–59 years age

group and 43.3% (92/212) in those older than 60 years. With regard to the control group, it is important to notice that, in recent years, the real prevalence of HCV infection in the general population of Southern Italy has been newly assessed by three studies performed in the Calabria, Campania and Apulia regions over more than 3800 subjects on the whole [2–4]. They have evidenced one of the highest overall anti-HCV prevalence rates compared with figures from other countries, reporting that the average prevalence of HCV infection in this area ranges from 12.6 to 26.0% with a clear age-distribution. In fact, the age-specific prevalence of HCV infection in Southern Italy ranges from 0 to 1.3% in subjects younger than 30 years, from 2.3 to 10.9% in 30–39 years age group, from 5.0 to 25.9% in 40–49 years age group, from 18.4 to 34.5% in 50–59 years age group and from 33.1 to 42.1% in those older than 60 years. The average prevalence, according to the same age groups, are 1.30, 8.45, 19.9, 30.2, and 37.7%, respectively. Comparing these data with those underlined in our study over 600 OLP patients, the emerging picture is that of a strong similarity, without statistically significant differences ($P = 0.05$) (Fig. 1). So, to understand whether OLP is really epidemiologically associated with HCV infection, we have to avoid the error of looking at the overall anti-HCV prevalence in the general population, and we need to compare the single age groups and the age-specific prevalence of HCV infection. What emerges from our 600 OLP patients, which is to our knowledge the biggest group of OLP patients in Italy, reflects the age-specific average prevalence of HCV infection in the general population of Southern Italy. These epidemiological findings point out a lack of evidence for an association between OLP and HCV infection in Southern Italy and seem to suggest that the data previously reported in Southern Italy and other HCV hyperendemic regions may be explained by the high prevalence of HCV infection in these areas. As consequence, our findings suggest that the reported epidemiological association between OLP and HCV infection may be merely casual and that OLP may not be categorized among extrahepatic manifestations of HCV infection, as reported in previous non-epidemiological studies. Nevertheless, we have to accept that OLP may have a different clinical behavior in patients with HCV infection and/or in those treated with interferon for hepatitis C, as we and other authors have described [5], hypothesizing a role of HCV and/or the interferon therapy in the modulation of the

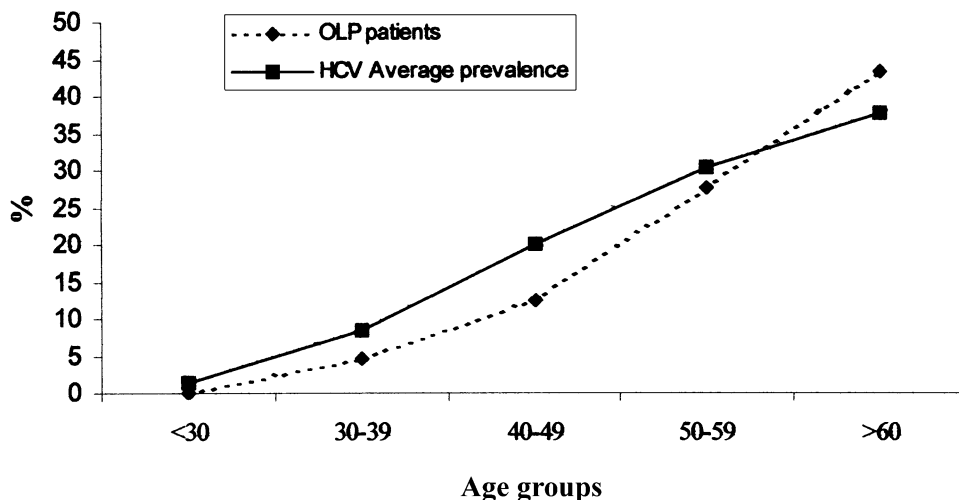


Fig. 1. Comparison of HCV prevalence between OLP patients and general population.

host immune response. With regard to previous studies which reported the evidence of an association between OLP and HCV infection, it is now possible to identify some errors in analytic procedures which could have led to incorrect results: (I) control groups identified without analyzing the age-specific prevalence of anti-HCV positivity; and (II) inadequacy of previous data towards the real prevalence of HCV infection in the general population. In conclusion, even if further epidemiological studies from other countries are needed, we suggest that the epidemiological analysis should be direct toward assessing the age specific prevalence of HCV infection in OLP patients in order to compare these data to the real age specific prevalence of HCV infection in the general population, including youngest and oldest people.

Michele D. Mignogna¹, Stefano Fedele¹, Lucio Lo Russo¹,
Elvira Ruoppo¹, Daniela Adamo¹, Lorenzo Lo Muzio²

¹Division of Oral Medicine, Department of Odontostomatological and Maxillo-Facial Sciences, University of Naples 'Federico II', Via Domenico Fontana 81, pal. 10, 80128 Naples, Italy, ²Institute

of Odontostomatology, School of Dentistry, University of Ancona, Ancona, Italy

References

- [1] Bellentani S, Miglioli L, Masutti F, Saccoccio G, Tiribelli C. Epidemiology of hepatitis C virus infection in Italy: the slowly unraveling mystery. *Microbes Infect* 2000;2:1757–1763.
- [2] Osella AR, Misciagna G, Leone A, Di Leo A, Fiore G. Epidemiology of hepatitis C virus infection in Southern Italy. *J Hepatol* 1997;27:30–35.
- [3] Guadagnino V, Stroffolini T, Rapicetta M, Costantino A, Kondili LA, Menniti-Ippolito F, et al. Prevalence, risk factors and genotype distribution of hepatitis C virus infection in the general population: a community-based survey in Southern Italy. *Hepatology* 1997;26:1006–1011.
- [4] Maio G, D'Argenio P, Stroffolini T, Bozza A, Sacco L, Tosti ME, et al. Hepatitis C virus infection and alanine transaminase levels in the general population: a survey in Southern Italy. *J Hepatol* 2000;33:116–120.
- [5] Mignogna MD, Lo Muzio L, Lo Russo L, Fedele S, Ruoppo E, Buccì E. Oral lichen planus: different clinical features in HCV-positive and HCV-negative patients. *Int J Dermatol* 2000;39:134–139.

PII: S0168-8278(02)00173-3

Rofecoxib-induced cholestatic hepatitis: treatment with molecular adsorbent recycling system (MARS)

To the Editor:

Rofecoxib is a new and increasingly popular non-steroidal antiinflammatory drug (NSAID) that acts via selective inhibition of cyclooxygenase-2 (COX-2) [1]. Rofecoxib is approved for treatment of acute pain in adults, primary dysmenorrhea and relief of the signs and symptoms of osteoarthritis. So far, no severe hepatic adverse effects have been published with the use of rofecoxib, but elevations of aminotransferases were observed in approximately 1% of patients in clinical trials [1].

Case report: A 52-year old woman presented with 3 weeks history of jaundice, increasing pruritus and malaise after 3 months of treatment with rofecoxib (25 mg/day), for osteoarthritis. The patient's medical history included hypertension and aortic valve replacement (1981). She reported no allergy and denied alcohol intake. Her long-standing medication (>4 years) included phenprocoumon, metoprolol, quinalapril, hydrochlorothiazide and estrogen (postmenopausal disorders), without any remarkable side effects. Physical examination showed severe jaundice. Laboratory